











Review

## External ventricular drainage - The most frequent neurosurgical procedure. A review and practical considerations

Marcelo Moraes Valença<sup>1,2</sup> , Luiz Severo Bem Junior<sup>3</sup> , Ana Cristina Veiga Silva<sup>4</sup> ,  
Elayne Cristina de Oliveira Ribeiro<sup>2</sup> , José Jailson Costa do Nascimento<sup>2</sup> ,  
Martina Falcão Valença<sup>5</sup> , Marcelo Andrade Valença<sup>2</sup> , Ubiratan Alves Vitorino da Silva<sup>4</sup> ,  
Luciana Patrícia Alves Andrade-Valença<sup>1,2</sup> , Hildo Rocha Cirne de Azevedo Filho<sup>4</sup> 

<sup>1</sup>Unimed Recife, Recife, Pernambuco, Brazil;

<sup>2</sup>Federal University of Pernambuco, Recife, Pernambuco, Brazil;

<sup>3</sup>College of Medical Sciences, Unifacisa University Center, Campina Grande-PB;

<sup>4</sup>Department of Neurosurgery, Hospital da Restauração, Recife, Pernambuco;

<sup>5</sup>Städtisches Klinikum Dresden, Dresden, Germany



Marcelo Moraes Valença  
mmvalenca@yahoo.com.br

Edited by:  
Fernando Cruz

**Keywords:**

External ventricular drainage  
Neurosurgery procedures  
Hydrocephalus

### Abstract

In the present article, the authors wish to review and comment on a few practical considerations regarding external ventricular drainage (EVD). External ventricular drainage is the most frequent procedure with intracranial access in neurosurgical practice. Despite its importance for saving lives, it still seems to be undervalued, being performed many times by young doctors in the early years of their neurosurgery residency program. In the vast majority, the technique is performed in an emergency scenario when there is a high risk of death for the individual. The main indication for performing an EVD is hydrocephalus. Increased ventricular volume due to difficulty in circulation or absorption of cerebrospinal fluid (CSF) can have numerous causes, such as intraventricular bleeding, infection, obstruction of CSF drainage pathways by intracranial tumors, cerebellar stroke/edema, and traumatic brain injury. Despite being a life-saving neurosurgical procedure, complications can occur; some are serious and can cause permanent neurological deficits and even death. Infection and hemorrhage are the most frequent complications. The most feared infection is ventriculitis, with high frequency when EVD remains for more than ten days. We conclude that the procedure for implanting an EVD is an intervention with potential risk and must be performed following rigorous protocols to avoid serious complications.

Received: June 13, 2022  
Accepted: July, 1 2022  
Published: December 12, 2022

## Introduction

External ventricular drainage (EVD) is the most frequent neurosurgical procedure. Despite its importance for saving lives, it still seems to be undervalued, being performed many times by young doctors in the early years of their neurosurgery residency program.

In the vast majority, the technique is performed in an emergency scenario when there is a high risk of death for the individual. The main indication for performing an EVD is hydrocephalus. Increased ventricular volume due to difficulty in circulation or absorption of cerebrospinal fluid (CSF) can have numerous causes. We highlight intraventricular bleeding, infection, obstruction of CSF drainage pathways by intracranial tumors, cerebellar stroke/edema, and traumatic brain injury.<sup>1,2</sup>

In the present article, the authors wish to review and comment on a few practical considerations regarding EVD.

### Narrative review

An average adult has a daily production of 450-500 ml of CSF. In the ventricular system and subarachnoid space, the volume of CSF is about 120 ml. Thus, it is not enough to remove the excess CSF in the ventricles but to leave drainage that continuously takes the CSF that is constantly produced and leads to the outside of the skull and drained in a closed container.

Despite being a life-saving neurosurgical procedure, complications can occur; some of them are serious that can cause permanent neurological deficits and even death.<sup>3</sup>

Infection and hemorrhage are the most frequent complications.<sup>1,4-6</sup> The most feared infection is ventriculitis, with high frequency when EVD remains for more than ten days.

Zakaria and coworkers<sup>2</sup> studied a total of 428 EVDs in 381 patients. The median EVD duration was ten days. Indications for the implantation of EVD were hemorrhage (51.9%), tumor (16.2%), trauma (12.8%), hydrocephalus (11.5%), cerebellar stroke (2.8%), and infection (3.1%). External ventricular drainage shunt-related complications were recorded in 8.3% (n = 32, with eight infections and 24 tract hemorrhages).

Computed tomographic of the head was performed in 346 consecutive patients who underwent bedside ventriculostomy.<sup>1</sup> The diagnoses were: subarachnoid

hemorrhage (44%), trauma (18%), and intracerebral hemorrhage/intraventricular hemorrhage (18%).<sup>1</sup> To examine the catheter placement, the authors classified the EVD as grade 1 (optimal placement in the ipsilateral frontal horn or third ventricle, 77%); grade 2 (functional placement in the contralateral lateral ventricle or non-eloquent cortex, 10%); and grade 3 (suboptimal placement in the eloquent cortex or nontarget CSF space, with or without functional drainage, 13%).<sup>1</sup> Hemorrhagic complications happened in 17 (5%) patients; four patients (1.2%) were symptomatic, with two (0.6%) requiring surgery.<sup>1</sup> They also evaluated the rates of suboptimal placement, which were highest in those subjects with midline shift (p=0.059) and trauma (p= 0.0001).<sup>1</sup> On the other hand, the rates of optimal placement were highest in those with subarachnoid hemorrhage (p=0.003) and when the catheter was placed ipsilateral to the side of midline shift (p=0.063).<sup>1</sup> Interestingly, neither the resident's training experience nor the placement side appeared to affect accuracy.<sup>1</sup> They concluded that bedside ventriculostomy is a safe and accurate technique for intracranial pressure monitoring and CSF drainage.<sup>1</sup>

We want to highlight an interesting article reported by the Infection in Neurosurgery Working Party of the British Society for Antimicrobial Chemotherapy<sup>7</sup> on the management of neurosurgical patients who develop postoperative meningitis or EVD-related ventriculitis. The expert group classified postoperative meningitis as bacterial or aseptic. Aseptic meningitis is comparatively more common than bacterial. It is not easy to distinguish between the two varieties in clinical practices.<sup>7</sup> Thus, the consensus suggested that all patients with the clinical and laboratory features of postoperative meningitis should receive empirical antibiotic therapy.<sup>7</sup> However, the antibiotics may be discontinued if a cultured sample of CSF is sterile after three days of incubation.<sup>7</sup>

Wong and colleagues<sup>8</sup> evaluated whether periodic changes of external ventricular drains would decrease CSF infection. They followed 103 patients who received external ventricular drains for more than five days without evidence of CSF infection.<sup>9</sup> The patients were randomized to routine change of ventricular catheter (every five days) or no change unless clinically indicated.<sup>9</sup> The CSF infection rates were 7.8% and 3.8%, respectively (p = 0.50). The authors concluded that regular changes of the ventricular catheter at five-day intervals did not lower the risk of CSF infection.<sup>9</sup> So, a single external ventricular drain can be used as

prolonged as clinically indicated.<sup>9</sup>

A recent study<sup>3</sup> was designed to determine possible risk factors for EVD infections. With this intention, all EVD insertions in an institution in the USA followed a standardized infection control protocol for EVD insertion and maintenance.<sup>3</sup> There were 479 EVDs placed in 409 patients, and nine culture-positive infections were observed during the study period.<sup>3</sup> The risk of infection within 30 days of EVD implantation was 2.2% (2.3 infections/1,000 EVD days).<sup>3</sup> Coagulase-negative *staphylococci* were recognized in 6 of the 9 EVD infections.<sup>3</sup> The statistical analysis identified the following risk factors: (1) patients with prior brain surgery associated with CSF diversion, (2) CSF leak around the catheter, and (3) insertion site dehiscence. Interestingly, duration of EVD use >7 days was not associated with infection risk (HR, 0.62; 95% CI, 0.07-5.45;  $p=0.669$ ).<sup>3</sup>

Commenting on catheter-related infection as a potentially life-threatening complication seen in EVD, there is a study<sup>10</sup> in which the authors examined the efficacy of EVD catheters impregnated with minocycline and rifampin in preventing bacterial infections. The authors executed a prospective, randomized clinical trial with adult patients implanted with an EVD catheter.<sup>10</sup> CSF samples were collected at the time of catheter insertion, at least every 72 hours while the catheter remained in place, and at the time of catheter removal. One hundred thirty-nine patients were allocated to the control group and 149 to the treatment group.<sup>10</sup> The antibiotic-impregnated catheters were one-half as likely to become colonized as the control catheters (17.9% compared with 36.7%, respectively,  $p<0.0012$ ).<sup>10</sup> Positive CSF cultures were seven times less frequent in patients with antibiotic-impregnated catheters than in the control group (1.3% compared with 9.4%, respectively,  $p = 0.002$ ).<sup>10</sup> The authors concluded that using EVD catheters impregnated with minocycline and rifampin can significantly reduce the risk of catheter-related infections.

A strict care protocol could reduce EVD-related ventriculitis.<sup>4,5</sup> In one report<sup>5</sup>, protocol violation was associated with a higher incidence of EVD-related ventriculitis. The absence of hair clipping, absence of a tunneled EVD, absence of shampooing, incorrect dressing change, inappropriate CSF bag or tap samplings, and EVD manipulation were considered protocol violations.<sup>5</sup> The authors performed a retrospective comparison of EVD-related ventriculitis incidence between control (161 EVD in 131 subjects) and selected patients who followed the protocol (216 EVD in 175 subjects) (EVD duration 2 to 42 days).<sup>5</sup>

There was a decrease in the incidence of patient-related ventriculitis from 12.2% to 5.7% ( $p<0.05$ ); a similar result was observed in the incidence of EVD-related ventriculitis (9.9% vs. 4.6%,  $p<0.05$ ).<sup>5</sup> The only statistically significant associations for infection were CSF leak and protocol violations.<sup>5</sup> The mean protocol violation score was 4 times higher in the infected versus the non-infected patients ( $p<0.0001$ ).<sup>5</sup> They suggested that EVD can be left safely, as prolonged as required, once meticulous care is taken for EVD insertion and nursing. The EVD duration appears not to affect infection incidence.<sup>5</sup>

Following this same reasoning, one study<sup>4</sup> showed that adherence to an evidence-based protocol for insertion and management of EVD significantly reduced the infection rate from 27% to 12%.

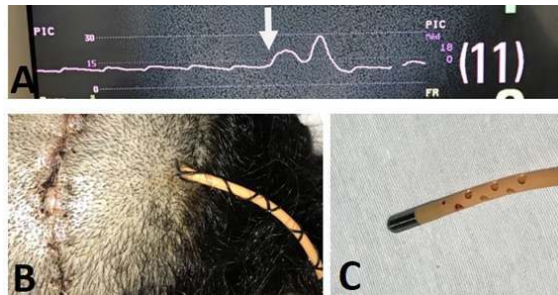
In a retrospective study<sup>11</sup> involving 199 patients (269 EVDs), the authors encountered 21 CSF infections (acinetobacter in 10). They concluded that the duration of drainage was not an independent predictor of infection, but multiple insertions of EVDs were a significant risk factor. The EVD infection was initially identified  $5.5 \pm 0.7$  days postinsertion (standard error of the mean). They interpreted the data as a pattern of infection, which is best explained by EVD-associated CSF infections acquired by the introduction of bacteria on insertion of the EVD rather than by subsequent retrograde colonization. Thus, elective EVD revision seems to increase infection rates, and this practice has been abandoned in the authors' institution.

A study<sup>9</sup> evaluated whether single-board spectrum antibiotic prophylaxis was as good as dual-specific antibiotic prophylaxis in patients with EVD. During two years, 255 eligible patients were recruited and randomized into two groups of antibiotic prophylaxis. Group A employed cefepime 2 g 12 hourly, and Group B employed dual antibiotics as ampicillin/sulbactam 3 g 8 hourly and aztreonam 2 g 8 hourly. As a result, there was no statistically significant difference in CSF infection rate [11.5% vs. 6.0%, ( $p=0.18$ ), respectively].<sup>9</sup>


It is essential to point out here that due to the proximity of the EVD catheter with catheters implanted in central veins used in anesthesia, there is a possibility that the anesthetist gets confused and injects anesthetics or other drugs into the ventricle via the EVD catheter.<sup>12</sup> Thus, leave the DVE drain away from the central vein catheter and signal the differences.<sup>12</sup>

Some EVD systems are coupled with pressure transducers so that while draining CSF from the

ventricle, it also measures intraventricular pressure (see Figure 1).



**Figure 1.** A. View of intraventricular pressure tracing in a patient with EVD and continuous monitoring of intracranial pressure. The white arrow shows the moment the patient performed the Valsalva maneuver through coughing, with an immediate increase in intracranial pressure in the baseline. B. Catheter exit site away from the burr hole where the catheter entered the intracranial cavity. C. Detail of the tip of the drainage catheter coupled with the pressure transducer.



**Figure 2.** Cerebrospinal fluid drainage bag. Note that there was a drainage of hemorrhagic CSF in this patient on the fifth postoperative day of surgery for an intraventricular tumor (left panel). The detail of the location where the CSF drips according to the height relative to the patient's head (Right panel).

## Conclusion

We conclude that the procedure for implanting an EVD is an intervention with potential risk and must be performed following rigorous protocols to avoid serious complications.

Marcelo Mores Valença  
<https://orcid.org/0000-0003-0678-3782>,  
 Luiz Severo Bem Junior  
<https://orcid.org/0000-0002-0835-5995>  
 Ana Cristina Veiga Silva  
<https://orcid.org/0000-0002-1149-4427>  
 Elayne Cristina de Oliveira Ribeiro  
<https://orcid.org/0000-0002-5243-3356>  
 José Jailson Costa do Nascimento  
<https://orcid.org/0000-0002-0365-665X>  
 Martina Falcão Valença  
<https://orcid.org/0000-0002-4085-3118>

Marcelo Andrade Valença  
<https://orcid.org/0000-0002-0824-0928>  
 Ubiratan Alves Vitorino da Silva  
<https://orcid.org/0000-0002-7715-8258>  
 Luciana Patrícia Alves Andrade-Valença  
<https://orcid.org/0000-0002-3487-0325>  
 Hildo Rocha Cirne de Azevedo Filho  
<https://orcid.org/0000-0002-1555-3578>

**Funding:** The authors received no specific funding for this work.

**Conflict of Interest:** On behalf of all authors, the corresponding author states that there is no conflict of interest.

**Author contributions:** The contribution was equal among the authors.

## References

1. Kakarla UK, Kim LJ, Chang SW, Theodore N and Spetzler RF. **Safety and accuracy of bedside external ventricular drain placement.** *Neurosurgery* 2008; 63(1 Suppl 1):ONS162-166; discussion ONS166-167 Doi:10.1227/01.neu.0000335031.23521.d00006123-200807001-00028 [pii]
2. Zakaria J, Jusue-Torres I, Frazzetta J, Rezaii E, Costa R, Ballard M, . . .Prabhu VC. **Effectiveness of a Standardized External Ventricular Drain Placement Protocol for Infection Control.** *World Neurosurg* 2021; 151(e771-e777 Doi:S1878-8750(21)00656-2[pii]10.1016/j.wneu.2021.04.113
3. Walek KW, Leary OP, Sastry R, Asaad WF, Walsh JM, Horoho J and Mermel LA. **Risk factors and outcomes associated with external ventricular drain infections.** *Infect Control Hosp Epidemiol* 2022; 1-8 Doi:10.1017/ice.2022.23S0899823X2200023X [pii]
4. Dasic D, Hanna SJ, Bojanic S and Kerr RS. **External ventricular drain infection: the effect of a strict protocol on infection rates and a review of the literature.** *Br J Neurosurg* 2006; 20(5):296-300 Doi: L7G33M5500212317 [pii]10.1080/02688690600999901
5. Korinek AM, Reina M, Boch AL, Rivera AO, De Bels D and Puybasset L. **Prevention of external ventricular drain--related ventriculitis.** *Acta Neurochir (Wien)* 2005; 147(1):39-45; discussion 45-36 Doi:10.1007/s00701-004-0416-z
6. Elvy J, Porter D and Brown E. **Treatment of external ventricular drain-associated ventriculitis caused by Enterococcus faecalis with intraventricular daptomycin.** *J Antimicrob Chemother* 2008; 61(2):461-462 Doi: dkm501[pii]10.1093/jac/

- dkm501
7. **The management of neurosurgical patients with postoperative bacterial or aseptic meningitis or external ventricular drain-associated ventriculitis.** Infection in Neurosurgery Working Party of the British Society for Antimicrobial Chemotherapy. *Br J Neurosurg* 2000; 14(1):7-12 Doi:10.1080/02688690042834
  8. Wong GK, Poon WS, Wai S, Yu LM, Lyon D and Lam JM. **Failure of regular external ventricular drain exchange to reduce cerebrospinal fluid infection: result of a randomised controlled trial.** *J Neurol Neurosurg Psychiatry* 2002; 73(6):759-761 Doi:10.1136/jnnp.73.6.759
  9. Wong GK, Poon WS, Lyon D and Wai S. **Cefepime vs. Ampicillin/Sulbactam and Aztreonam as antibiotic prophylaxis in neurosurgical patients with external ventricular drain: result of a prospective randomized controlled clinical trial.** *J Clin Pharm Ther* 2006; 31(3):231-235 Doi: JCP729[pii]1111/j.1365-2710.2006.00729.x
  10. Zabramski JM, Whiting D, Darouiche RO, Horner TG, Olson J, Robertson C and Hamilton AJ. **Efficacy of antimicrobial-impregnated external ventricular drain catheters: a prospective, randomized, controlled trial.** *J Neurosurg* 2003; 98(4):725-730 Doi:10.3171/jns.2003.98.4.0725
  11. Lo CH, Spelman D, Bailey M, Cooper DJ, Rosenfeld JV and Brecknell JE. **External ventricular drain infections are independent of drain duration: an argument against elective revision.** *J Neurosurg* 2007; 106(3):378-383 Doi:10.3171/jns.2007.106.3.378
  12. Drake JM and Crawford MW. **Near-miss injection of an anesthetic agent into a cerebrospinal fluid external ventricular drain: special report.** *Neurosurgery* 2005; 56(5):E1161; discussion E1161