










## Bronchial anomaly with connection of the right upper lobe bronchus to the trachea

Pedro Pinheiro Barros<sup>1</sup> , Henry Martins Soares Fortes<sup>1</sup> , Ana Júlia Xavier de Mendoza<sup>2</sup> ,  
Klayton Moura Saraiva Filho<sup>1</sup> , Lorena Rodrigues Pellegrino de Azevedo<sup>1</sup> ,  
Marina Monteiro e Silva Rocha<sup>1</sup> , Victória dos Santos França<sup>1</sup> , Robertina Pinheiro Roberto<sup>3</sup> ,  
José Williams Alves Pinto<sup>4</sup> 

<sup>1</sup>Universidade de Pernambuco, Recife, Pernambuco, Brasil.

<sup>2</sup>Faculdade Pernambucana de Saúde, Recife, Pernambuco, Brasil.

<sup>3</sup>Universidade Federal do Cariri, Juazeiro do Norte, Ceará, Brasil.

<sup>4</sup>Unimed Cariri, Juazeiro do Norte, Ceará, Brasil.



Pedro Pinheiro Barros

E-mail: henry.fortes@upe.br

Edited by:

Marcelo M. Valença

Keywords:

Tracheal bronchus

Bronchoscopy

Pneumology

Figure 1 shows an image of a bronchoscopy with a view of the carina. Examination shows a bronchial anomaly with a connection of the right upper lobe bronchus to the trachea. This is the case of a 59-year-old woman complaining of pain in the right hemithorax after mild COVID-19 infection, presenting with heterogeneous opacity and cavitation in the right lung apex on chest X-ray and with negative tests for tuberculosis.

Bronchoscopy is an important method of etiological and anatomical diagnosis of respiratory system pathologies.<sup>1</sup> Its emergence allowed the study of the anatomical characteristics of the airways and their correlation with respiratory symptoms.<sup>1,2</sup> Bronchoscopy data led to the finding of a greater presence of bronchial anomalies involving the right upper lobe bronchus.<sup>3</sup> However, an abnormal bronchial origin of the trachea is a rare event compared to other cataloged alterations.

In the right upper lobe, the presence of a tracheal bronchus is estimated between 0.1 to 2% in bronchographic studies, while the presence of a tracheal bronchus supplying the entire right upper lobe has a frequency of 0.2% and is called porcine bronchus.<sup>4,5</sup> Such alteration is usually asymptomatic, being discovered by imaging tests such as computed tomography or bronchoscopy, which does not rule out the possibility of causing complications to the patient's respiratory health.<sup>2</sup>

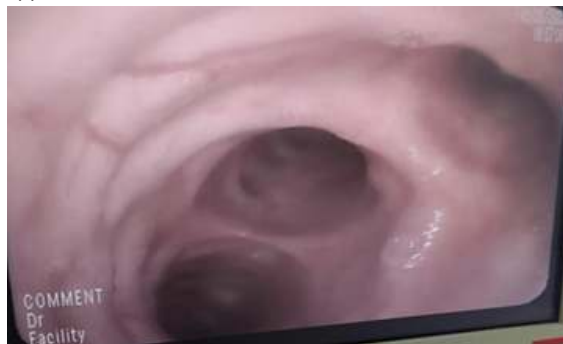It is known that the bronchial bifurcations constitute one of the defense mechanisms of the respiratory tree, contributing to the retention of secretions and their subsequent elimination by the cells of the immune system and by the hair cells of the airways. Thus, respiratory stress symptoms appear when bronchial vascular abnormalities are present, with symptoms ranging from the presence of recurrent infections, chronic cough, hemoptysis, and stridor.<sup>1,2,5</sup>

Submitted: August 3, 2022

Accepted: August 13, 2022

Thus, knowledge of bronchial abnormalities is important both for health professionals who work in respiratory endoscopy and thoracic radiology and for physicians who work in the treatment of respiratory tract disorders.

**Figure 1.** Bronchoscopy showing a connection of the right upper lobe bronchus with the trachea at the level of the carina.



**Funding:** This study did not receive any funding.

**Conflict of interest:** There is no conflict of interest.

**Authors Contribution:** The authors contributed equally to the writing of the manuscript.

Pedro Pinheiro Barros

<https://orcid.org/0000-0002-0577-430X>

Henry Martins Soares Fortes

<https://orcid.org/0000-0003-3963-9058>

Ana Júlia Xavier de Mendoza

<https://orcid.org/0000-0003-4324-899X>

Klayton Moura Saraiva Filho

<https://orcid.org/0000-0003-3778-8930>

Lorenna Rodrigues Pellegrino de Azevedo

<https://orcid.org/0000-0002-5995-5130>

Marina Monteiro e Silva Rocha

<https://orcid.org/0000-0003-3230-7528>

Victória dos Santos França

<https://orcid.org/0000-0001-6196-8822>

Robertina Pinheiro Roberto

<https://orcid.org/0000-0002-9299-5599>

José Williams Alves Pinto

<https://orcid.org/0000-0002-5234-4783>

## Referências

1. Ghaye, B., Szapiro, D., Fanchamps, J. M., & Dondelinger, R. F. (2001). **Congenital bronchial abnormalities revisited.** *Radiographics : a review publication of the Radiological Society of North America, Inc*, 21(1), 105–119. <https://doi.org/10.1148/radiographics.21.1.g01ja06105>
2. Sun, X. W., Lin, Y. N., Ding, Y. J., Li, S. Q., Li, H. P., & Li, Q. Y. (2021). **Bronchial Variation: Anatomical Abnormality May Predispose Chronic Obstructive Pulmonary Disease.** *International journal of chronic obstructive pulmonary disease*, 16, 423–431. <https://doi.org/10.2147/COPD.S297777>
3. Brock, R. C. (1954). **The anatomy of the bronchial tree: with special reference to the surgery of lung abscess.** Oxford University Press.
4. Ritsema, G. H. (1983). **Ectopic right bronchus: indications for bronchography.** *AJR Am J Roentgenol.* 140, 671–674.
5. Lemoine, J. M., Gagnon, A. (1952). **Principaux modes de division et anomalies anatomiques de la trachée et des bronches.** *Bronches*, 2, 409–421.