

Review

Anatomy, modern histology, and their mentors

Elayne Cristina de Oliveira Ribeiro¹ , Erlene Roberta Ribeiro dos Santos¹ ,
Rita de Cássia Ferreira Valença² , Marcelo Moraes Valença¹ 

¹Federal University of Pernambuco, Recife, Pernambuco, Brazil

²Restauração Hospital, Recife, Pernambuco, Brazil



Elayne Cristina de Oliveira Ribeiro
elayne.oriheiro@ufpe.br

Edited by:

Juliana Ramos de Andrade

Keywords:

Anatomy modern
Anatomists
Medicine history
Medical education

Abstract

Anatomy is a secular science that had contributions from great anatomists, mainly doctors. In the 16th century, modern anatomy emerged, and the studies of the physician and anatomist Andreas Vesalius, "father of modern anatomy", corrected the errors of his predecessors through human dissection and revolutionized the writing of anatomy with his work. Almost 200 years later, Marie François Xavier Bichat is "father of histology", contributed significantly to the description of tissues, expanding the studies of macroscopic anatomy to microscopic. In this article, the authors revisit the findings of anatomists notorious and their significant preliminary contributions to the current planning of surgical interventions.

Submitted: July 1st, 2022

Accepted: July 15, 2022

Introduction

The modern age refers to the historical period between the 15th and 18th centuries. The modern concept conceived by the intellectuals of that time meant to be synchronized with the advances of science, new ideas, and not just to believe in transcendence or divinity. These aspects made the milestones of that period possible, such as the cultural renaissance, religious reforms, commerce expansion, and maritime.

Before the 16th century, the human body was the scene of theories, which tried to explain its functioning. In this process, some anatomists were important (Figure 1). Initially, with attention to the anatomist and doctor Galen of Pergamon (129-199). His contributions were in anatomy, physiology, and medicine, perpetuated for about fourteen centuries, refuted in the renaissance period.




Figure 1. Timeline of important anatomy names.

Galen's work was, for a long time, the most relevant reference in anatomy, being accessible by the translation from Greek to Latin. His dissections were in animals, such as dogs and monkeys; their interpretations have been extended to the human body; this generated successive anatomical errors. Andreas Vesalius later contested his observations using the dissection of human bodies.^{1,2}

Galen's studies allowed to demystify the belief that arteries had the function of transporting "air"; described the veins and arteries; the heart valves; and made important considerations about blood circulation; differentiated the seven pairs of cranial nerves; made relations between the urinary bladder and the kidneys.^{1,3} In addition, he worked as a doctor at social levels distinct, different ages patients, in urban and rural areas, in a period of resource scarcity.⁴

The teaching of anatomy faced obstacles such as the scarcity of corpses for dissection, which was only legally permitted in the bodies of criminals sentenced to hang, as it was part of the death sentence to deny the dignified criminal burial in sanctified soil by the church.² The number of criminals in this condition was insufficient to provide the necessities of teaching anatomy, which made space for an illegal market, in which thieves violated the tombs to steal the corpses and sell them to medical schools.⁵

In this article, the authors revisit the findings of notable anatomists and their significant preliminary contributions that elucidate and enable the current planning of surgical interventions.

The anatomists

Andreas Vesalius (1514-1564) from Brussels was considered the father of modern anatomy (Figure 2). Before formal medical education, he studied the collections of treaties and abstracts of his doctors and pharmacists' family. In (1528) at the University of Louvain, he dedicated himself to the study of languages (Greek, Latin, and Hebrew), but he well understood only Latin.^{2,6}




Figure 2. Andreas Vesalius from Brussels (1514-1564).

At the University of Paris (1533-1536), he entered the medical career. At the time, the practice of dissection was still incipient at the university, obtaining this knowledge mainly on his initiative.^{2,7} The work of Galen was the most prominent reference in Anatomy

when Vesalius was a student.⁷

In Padua (1537), Vesalius immersed himself in the study of anatomy, and the institution contemplated the dissection of cadavers.⁸ In 1537, at the age of 23, after undergoing a dissection evaluation, Vesalius received Doctor of Medicine's title. In sequence, it became a teacher of surgery and anatomy at the renowned university.^{2,8} In classes, he used dissection as the central pillar, while his first drawings aimed to improve teaching in medicine.^{9,10}

Before dissecting bodies, still a medical student, Vesalius explored cemeteries and deepened his bones studies.² His experience in dissection began in medical school, and improved as a teacher, mainly by leaving the position of ostensor and lector for a dissector, performing the function of 3 in 1.⁶

When he left the teaching profession, he went to work as a doctor for Carlos V emperor, which allowed him a comfortable social position.⁷ The cause of his death is full of mysteries, and his body has never been located. Several theories try to find why Vesalius left Italy on a pilgrimage towards Jerusalem, from which he never returned. The most coherent theory is that a shipwreck occurred and his body found on the beach, recognized and then buried on the island of Zante in Greece.²

Another great name in anatomy and medicine was Marie François Xavier Bichat (1771-1802), born in Thoirette - France (Figure 3). Despite fulfilling the life cycle very early, he was scientifically very productive, especially in the last three years of his life. He left a legacy for several areas: Histology, Anatomy, Pathology, Biology, and Medicine.



Figure 3. Marie François Xavier Bichat (1771-1802).

In 1791 he received medical training at the Grand Hôtel-Dieu in Lyon, the medical surgeon Marc-Antoine Petit intruded him on anatomy and surgery.^{11,12} This place was a great reference for the study of medicine.^{13,14}

In Paris from 1793-1795, he received instructions from the surgeon Pierre-Joseph Desault, who was his great friend in addition to being a teacher.¹²⁻¹⁴ Desault was a famous doctor in Paris and published his surgical findings, mentored students, and was editor of the *Journal de Chirurgie*. After Desault's death, Bichat published his findings in 4 volumes, the last was a biography dedicated to his master. He was responsible for autopsying Desault's body and revealed the real cause of his death.¹³

Bichat in (1799) abandoned medicine and devoted himself entirely to anatomy studies through the dissection of cadavers. Also, dedicated to research by carrying out experiments on animals.¹³ His insistence on dissection and research led to the publication of books several.

Bichat's death was premature, at 31 years old, the cause seems inconclusive among the authors, one of the hypotheses points to tuberculosis. Before dying, Bichat performed necropsies, in six months, of about 600 corpses.^{11,14}

Your legacies

The dissection of unauthorized bodies was used by these anatomists to answer questions about the human body. Without the dissection of bodies, it would not be possible to refute the definitions of Galen.⁷ Through this technique, it was possible to write significant works, contributing to anatomy with precision.

The first work of Vesalius was *Tabulae Sex* (1538). This work consisted of drawings six in a dimension never seen before.^{2,5} However, in this work, especially in the part of the heart and vessels, there were still errors from the Galen theories.¹⁵

Vesalius was a teacher who surprised in the anatomy classes, dissecting for students and contradicting concepts through demonstrations on the corpse.^{5,10} In Padua as teaching, he conceives *De Humani Corporis Fabrica*, great work, published in two editions and consecrated until today. Mainly for the beauty of his images with the dead in positions that imitate life, walking in gardens, and even showing feelings.

The first edition was launched in 1543 (when the

author was 25 years old), but it probably started to be written soon after the publication of *Tabulae Sex* the work was a success and had some criticisms. The most important was the revolution in writing anatomy combining detailed illustrations and texts, breaking the traditionalism of existing books.

The book was systematized in seven parts composed of bones, muscles, circulatory system, nervous system, abdomen, heart, and lungs, with the seventh section dedicated to the brain.¹⁶

The second edition in (1555), was an update of the first.¹⁰ This time, *De Humani Corporis Fabrica* presented a thick paper, rigorous textual revision, and the addition of chapters with physiological experiments.² Both editions were printed by woodcuts, and the richness of detail in the illustrations was impressive.¹⁰ Vesalius was consecrated as the "Father of Modern Anatomy," and *De Humani Corporis Fabrica* encouraged the use of illustrations in anatomy books.

Vesalius refuted several theories in different fields. In religion, it proved that men and women have the same amount of ribs. He left an important job to understand the human body mechanics when he managed to detail the muscle structures in the dissections illustrations. Refuted the theory that the center of emotions resided in the heart, claiming that nerve structures originated in the brain, and they are responsible for systemic control.⁷

In art, he dared in the richness of details of the illustrations, bringing "life to the corpse" before illustrated inertly, as an object. In Vesalius' works, drawn in stripped positions, everyday situations, movement, generating a new scientific and artistic perspective. The printing of colored figures also presented an innovation in modern anatomy, in addition to allowing a better understanding of anatomical structures by medical scholars of the time, as in the abbreviated edition of the "Epitome".⁸ He made human anatomy a scientific discipline because he knew that his in-depth knowledge was fundamental to the practice of surgery.⁵

Currently, eponyms have fallen into disuse, but we must not forget that the Vesalius name was used, a long time, in these structures: sphenoidal emissary foramen (foramen of Vesalius); tracheobronchial lymph nodes (Vesalius glands); inguinal ligament (Vesalius ligament); emissary vein (vein of Vesalius).

The time that separates Vesalius from Bichat is about 200 years. When Bichat worked as a doctor, he

criticized his professional colleagues who diagnosed diseases only related to symptoms and defended body autopsies to improve the doctors is diagnosis. Later, the importance of necropsy was recognized in Paris.¹⁴

Bichat's studies of organs as dissociable units made up of various tissues gave him the title "Father of Modern Histology" without using a microscope.¹⁴ He combined anatomical techniques and chemistry knowledge, such as maceration, corrosion with acids, boiling. Through these observations, Bichat made the first definition of "tissues" and concluded that an organ is a set of different tissues.¹⁴ His experiments marked the transition from the study of macroscopic to microscopic anatomy.

Bichat was adept at vitalism and believed that a vital force led functions and physiological changes in the body, and this could not be explained by physical and chemical laws.¹¹

Several books were published in a short period. The *Traité des Membranes en Général, De Diverses Membranes en particulier* (1799), classified 21 types of tissues, associating tissue lesions with pathologies, which brought significant contributions to the field of pathology. *Recherches physiologiques sur la vie et la mort* (1800) established differences about organic and animal life; concepts defined as sensitivity and contractility; symmetry and asymmetry of the organs. *Anatomie Générale, applied to the physiology and medicine of* (1801), was his most famous work. His last publication was *Traité D'Anatomie Descriptive*, which was designed for five volumes, but only two published in life. After his death, their students published three more volumes.^{11,13,14}

Some eponyms with the name of Bichat were used to identify different structures of the human body: pterygopalatine fossa (Bichat fossa); lymph nodes (Bichat lymph nodes); the ilio-hypogastric, ilioinguinal and lateral femoral cutaneous nerve (Bichat cutaneous muscle nerves). Finally, the adipose body of the cheek (Bichat ball), which its removal occurs through Bichectomy surgery.¹⁴

Past and present

The first impressions of Vesalius's work in woodcut showed excellent writing. The images brought significant contributions to new learning, as they served as a basis for current studies of 3D neuroanatomy.

The seventh volume of *De Humani Corporis Fabrica* is dedicated to the study of the brain, containing several images about the organ, showing Vesalius' interest in

neuroscience.^{5,10} Because of the neuroanatomy volume, has considered the founder of modern neurosurgery.¹⁷

It is possible to observe in the cerebral drawings of the Vesalius works that in the head cross sections, the cortical region is not detailed in the left and right cerebral hemispheres (LCH) and (RCH), respectively (Figures 4 and 5).

hemisphere (LCH and RCH, respective) with a small degree of detail. The longitudinal fissure (LF) is quite accentuated. The genu (CCG) and splenium (CCS) of the corpus callosum can be visualized. B. T1-weighted MRI, without contrast, adult, axial section. Evidence of the same structures.

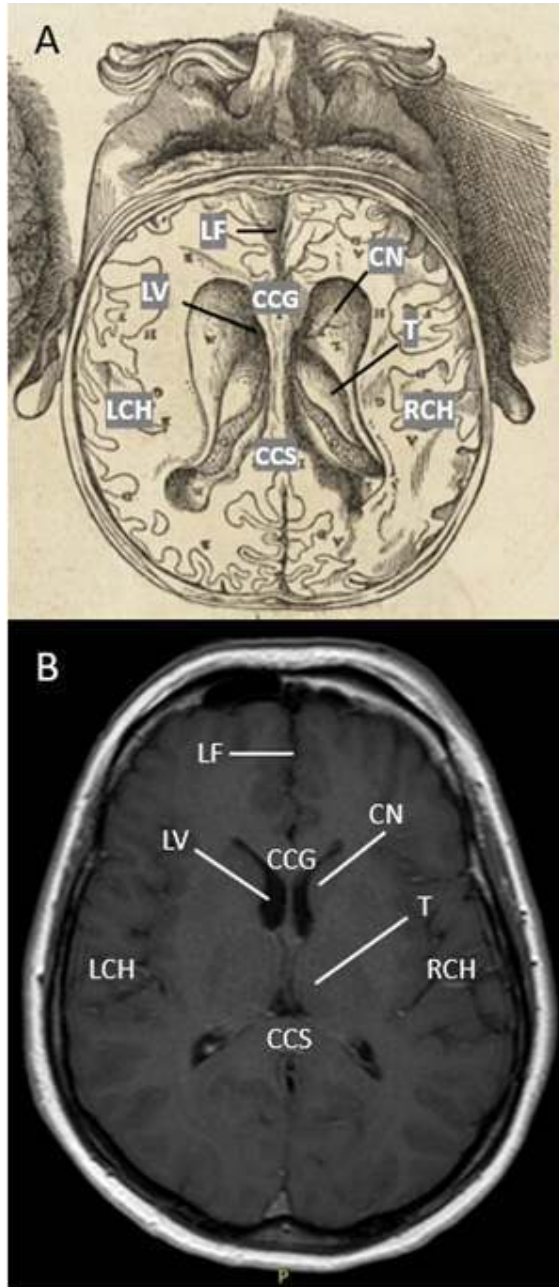


Figure 4. A. Illustration of the De Humani Corporis Fabrica. Adult head, coronal plane, in a circular section without calvaria.¹⁸ Observe in detail the nuclei of the base, such as the thalamus (T) and Caudate Nucleus (CN) and the lateral ventricle (LV). The cortical region of the sulci and gyri, Left and right cerebral

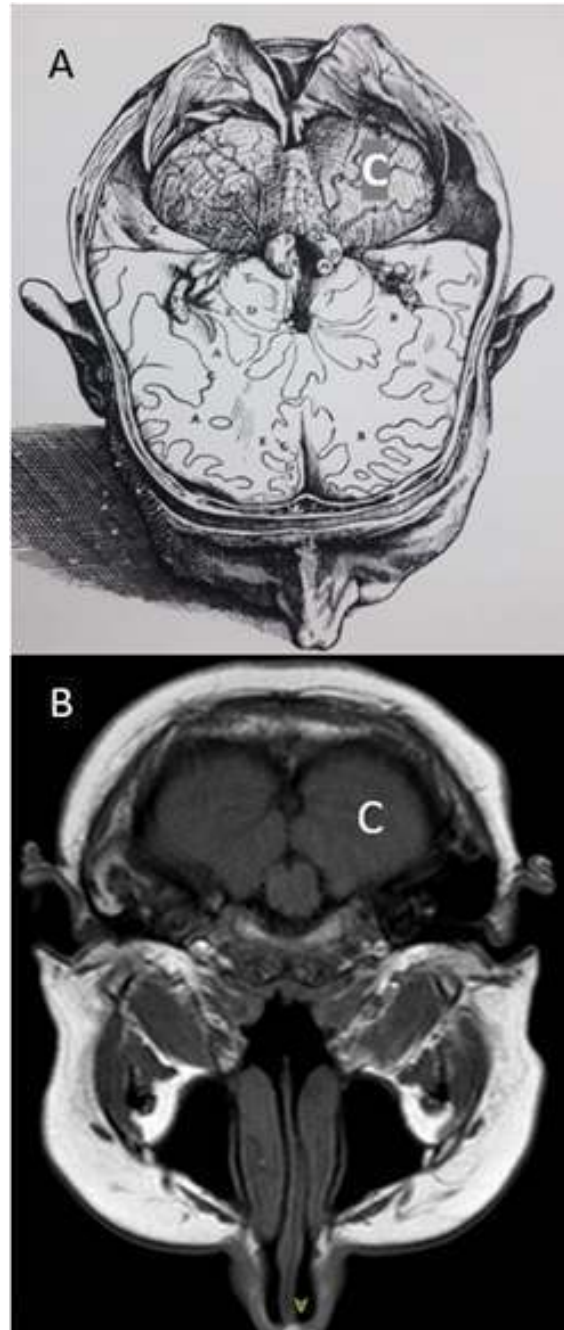


Figure 5. A. Illustration of the De Humani Corporis Fabrica.² B. T1-weighted MRI, without contrast. The images are at different levels of section. (A) Observe that the cerebellum (C) approaching reality. Again, little importance to the details of the cortical region, which contrasts with structure C.

The cerebral hemisphere has not a representation surface of the sulcis and gyri of brain (Figure 6). However, these illustrations were essential to support other works.¹⁷

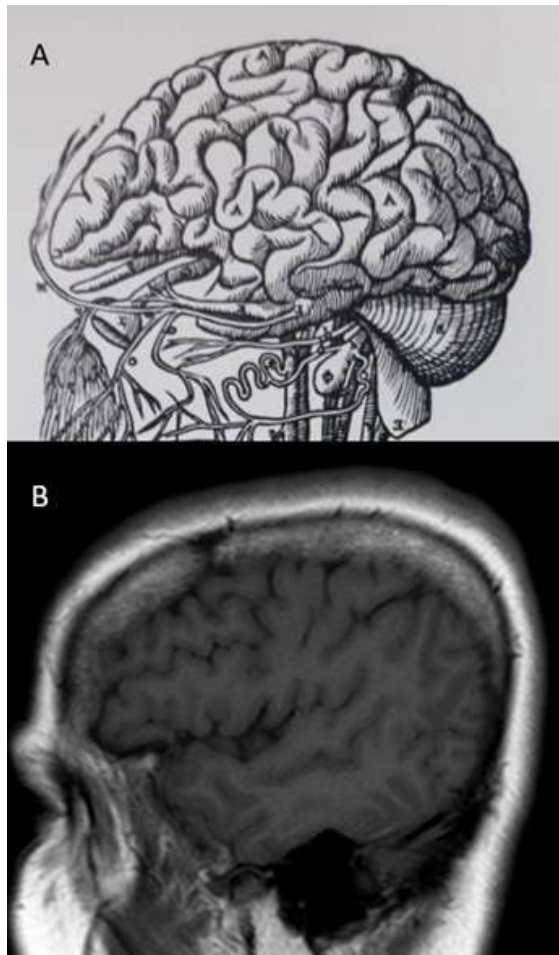


Figure 6. A. The cerebral hemisphere of the *De Humani Corporis Fabrica*. The illustrations of the gyri have accentuated volume and markings. The sulci were not described, especially the central and lateral sulci.² B. T1-weighted MRI, without contrast, in the same perspective as the illustration, showing the lateral sulci in evidence.

In the 19th century, Gray and Testut & Latarjet were books renowned references in teaching anatomy, remaining to this day. Testut is considered the "Bible of Anatomy." Both have original illustrations with monochrome and some with four palettes of color used to highlight specific structures such as arteries, veins, nerves, and muscles.¹² The anatomy atlases became popular with students. They proposed to replace the text with illustrations, the organs and structures of bodies appear in different viewing sections, the illustrations are colored, and some produced with digital resources.¹⁸

In medicine, advancement of imaging exams such as high-field functional magnetic resonance imaging (MRI), it was possible to view the human body dynamically in vivo. In neuroimaging, it was monitoring brain activities, blood flow, and cerebrospinal fluid in real-time.

In conclusion, the illustrations and descriptions contained in the works of Andreas Vesalius allowed a significant leap in anatomy. Marie François Xavier Bichat for histology, through her experiments with human organs until reaching the tissues. Both lived something in common, the experience of dissection, leaving as a legacy a more precise understanding of the human body, and, consequently, the advance of medicine.

References

1. Ajita R. **Galen and His Contribution to Anatomy: A Review.** *J Evol Med Dent Sci* 2015;4(26):4509-4516 Doi:10.14260/jemds/2015/651
2. Saunders JB and O'Malley C. **Andreas Vesalius de Bruxelas. De humani Corporis Fabrica. Epitome. Tabulae Sex.** São Paulo, SP: Ateliê Editorial; 2002. 15-42 p.
3. Li Ching Ng A, Rosenfeld JV and Di Ieva A. **Cranial Nerve Nomenclature: Historical Vignette.** *World Neurosurg* 2019;128(299-307 Doi:10.1016/j.wneu.2019.05.036
4. Mattern S. **Galen and his patients.** *The Lancet* 2011;378(9790):478-479 Doi:10.1016/s0140-6736(11)61240-3
5. Hymans LS. **Bruxelles à travers les Âges [Internet].** 1884 Available from: <https://archive.org/details/bruxellestravers01hyma/page/n6/mode/1up?view=theater>
6. Cambiaghi M. **Andreas Vesalius (1514–1564).** *J Neurol* 2017;264(8):1828-1830 Doi:10.1007/s00415-017-8459-2
7. Gomes MdM, Moscovici M and Engelhardt E. **Andreas Vesalius as a renaissance innovative neuroanatomist: his 5th centenary of birth.** *Arq Neuropsiquiatr* 2015;73(2):155-158 Doi:10.1590/0004-282x20140201
8. Zampieri F, ElMaghawry M, Zanatta A and Thiene G. **Andreas Vesalius: Celebrating 500 years of dissecting nature.** *Glob Cardiol Sci Pract* 2015;2015(5):66 Doi:10.5339/gcsp.2015.66
9. Delafontaine PM. **Portrait of Marie François Xavier Bichat 1799** Available from: <https://www.repro-tableaux.com/a/delafontaine-pierre-maxim/portrait-of-francois-xavi.html>
10. Afshar A, Steensma DP and Kyle RA.

- Andreas Vesalius and De Fabrica.** *Mayo Clin Proc* 2019;94(5):e67-e68 Doi:10.1016/j.mayocp.2019.03.018
11. Fye WB. **Marie-François-Xavier Bichat.** *Clin Cardiol* 1996;19(9):760-761 Doi:10.1002/clc.4960190918
 12. Fessy MH, Carret JP and Viste A. **The history of anatomy teaching in Lyon University: in the footsteps of Rabelais, Petit, Lisfranc, Testut and Latarjet, and many others.** *Surg Radiol Anat* 2019;41(10):1129-1133 Doi:10.1007/s00276-019-02321-9
 13. Androutsos G, Diamantis A and Vladimirov L. **Cancer's conceptions of Marie François Xavier Bichat (1771-1802), founder of histology.** *J buon* 2007;12(2):295-302.
 14. Shoja MM, Tubbs RS, Loukas M, Shokouhi G and Ardanian MR. **Marie-François Xavier Bichat (1771-1802) and his contributions to the foundations of pathological anatomy and modern medicine.** *Ann Anat* 2008;190(5):413-420 Doi:10.1016/j.aanat.2008.07.004
 15. Zampieri F, Basso C and Thiene G. **Andreas Vesalius' Tabulae anatomicae sex (1538) and the seal of the American College of Cardiology.** *J Am Coll Cardiol* 2014;63(7):694-695 Doi:10.1016/j.jacc.2013.09.031
 16. Rezende JM. **À sombra do plátano: crônicas de história da medicina.** São Paulo, SP: SciELO-Editora Fap-Unifesp; 2009
 17. Splavski B, Rotim K, Lakičević G, Gienapp AJ, Boop FA and Arnautović Kl. **Andreas Vesalius, the Predecessor of Neurosurgery: How his Progressive Scientific Achievements Affected his Professional Life and Destiny.** *World Neurosurg* 2019;129(202-209) Doi:10.1016/j.wneu.2019.06.008
 18. Vasalius A. **De Humani Corporis Fabrica. Plate 8** [Internet]. 1543 Available from: <https://thepsychologist.bps.org.uk/volume-30/april-2017/five-depictions-brain>